

Development of a Training Model for Laparoscopic Common Bile Duct Exploration

Alexis Sánchez, MD, Omaira Rodríguez, MD, Gustavo Benítez, MD,
Renata Sánchez, MD, Liliana De la Fuente, MD

ABSTRACT

Background: Training and experience of the surgical team are fundamental for the safety and success of complex surgical procedures, such as laparoscopic common bile duct exploration.

Methods: We describe an inert, simple, very low-cost, and readily available training model. Created using a “black box” and basic medical and surgical material, it allows training in the fundamental steps necessary for laparoscopic biliary tract surgery, namely, (1) intraoperative cholangiography, (2) transcystic exploration, and (3) laparoscopic choledochotomy, and t-tube insertion.

Results: The proposed model has allowed for the development of the skills necessary for partaking in said procedures, contributing to its development and diminishing surgery time as the trainee advances down the learning curve. Further studies are directed towards objectively determining the impact of the model on skill acquisition.

Conclusion: The described model is simple and readily available allowing for accurate reproduction of the main steps and maneuvers that take place during laparoscopic common bile duct exploration, with the purpose of reducing failure and complications.

Key Words: Training, Common bile duct, Exploration, Choledocholithiasis.

INTRODUCTION

Laparoscopy has gained much acceptance during the past decade. Since the introduction of laparoscopic cholecystectomy and its well-known benefits of reduced pain, shorter hospitalization time, quick return to normal routine, and optimal esthetic results,¹⁻³ the number of procedures undertaken via minimally invasive surgery has been constantly increasing.

Mastering of laparoscopic cholecystectomy led laparoscopic biliary surgery to the next step, that is, laparoscopic common bile duct exploration. The feasibility and safety of this technique has been demonstrated by various authors,⁴⁻¹⁵ with a success rate between 86% and 100%, morbidity around 7%, and mortality <1%.

Training of the surgical team and the availability of appropriate surgical material are fundamental factors in achieving satisfactory results.^{15,16}

Traditionally, the learning of new surgical techniques has been achieved through observation and realization under the supervision of experienced surgeons. However, this type of training is costly for the institutions, besides having obvious medical and legal implications.¹⁶⁻¹⁸

Training using animal models is an excellent alternative that has been used for training in several procedures such as cholecystectomy,²⁰ hepatectomy,²¹ and treatment of portal hypertension,²² amongst others. The use of porcine organs *ex vivo* has also been described.²³

The porcine model for exploration of the biliary tract was first described by Cameron et al²⁴ in 1994 and later by Watson et al.²⁵ More recently in Latin America, Pejkol et al²⁶ described a similar model and studied its impact on the training of surgical residents.

The problem with animal models lies in the cost, particularly in the case of the biliary tract, because it requires a previous intervention for the ligation of the biliary tract, and keeping the animal in captivity for at least a week to achieve an appropriate dilation of the choledochus to allow for instrumentation.

The experience in Venezuela with this type of surgery is limited. We have described our first experience in the

Central University of Venezuela, Surgery Department III, University Hospital of Caracas, Caracas, Venezuela (all authors).

This study was funded by the Scientific and Humanistic Development Center of the Central University of Venezuela.

Address correspondence to: Aléxis Sanchez, MD, Avenida Principal de Santa Sofía, Torre Alfa, Piso 9, Consultório 9C, Santa Sofía, El Cafetal, Caracas, Miranda 1061, Venezuela. Telephone: 058 414 3310944, Fax: 058 212 9856257, E-mail: dralexissanchez@hotmail.com

DOI: 10.4293/108680810X12674612014464

© 2010 by JSLS, *Journal of the Society of Laparoendoscopic Surgeons*. Published by the Society of Laparoendoscopic Surgeons, Inc.

technique at the University Hospital of Caracas¹⁵; we consider it to be a complex technique where training of the surgical team is of the essence.

Due to what has been described within the laparoscopic surgery workshop, the objective of which is to school general surgery residents in laparoscopic surgery, we have suggested the development of an inert model that would be a readily available and low-cost tool for training in the instrumentation of the biliary tract, which we will now describe.

MODEL DESCRIPTION

The materials required for the construction of this model are a black box that is normally used for practicing laparoscopic techniques, available in the majority of centers, and easily obtainable medical surgical materials as are as follows (**Figure 1**):

1. Latex vesical catheters
2. Silastic vesical catheters
3. Polyglactin 910 sutures (Vicryl) or polyester (Ethibond) due to its easy management
4. t-tube (Kehr).

Laparoscopic instruments for this practice must include basic dissection and prehension instruments along with 2 laparoscopic needle holders. Additional requirements include a helicoidal basket or Dormia basket for practicing calculi extraction.

In our described model, we aspire to reproduce the fun-

damental steps of laparoscopic biliary tract surgeries, such as:

1. Intraoperative cholangiography
2. Transcystic biliary tract exploration
3. Laparoscopic choledochotomy and t-tube insertion.

INTRAOPERATIVE CHOLANGIOGRAPHY

Intraoperative cholangiography constitutes the initial step in the laparoscopic instrumentation of the biliary tract. For practicing this step, we used a portion of a vesical catheter joined perpendicularly to another, thus simulating the manner in which the cystic duct joins the main biliary tract (**Figure 2**).

This model allows the surgeon to simulate the necessary movements and steps, ie, the partial section of the cystic duct for later insertion and progress of the cholangiography catheter towards the biliary tract, as is performed during live surgery.

TRANSCYSTIC EXPLORATION

For the construction of this model, we require a Silastic vesical catheter that has been modified using a stylet to simulate the cystic duct and the main biliary tract.

The use of a transparent catheter allows the surgeon to practice the capture of fictitious calculi in a 2-dimensional plane, as would be done in live surgical exploration guided by fluoroscopy, thus allowing familiarization with

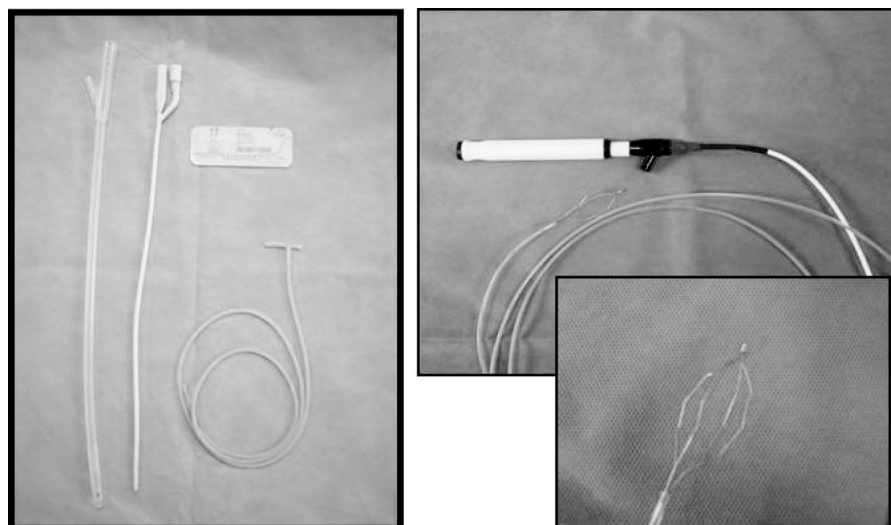


Figure 1. Material used for the elaboration of the training model.




Figure 2. Intraoperative cholangiography (IOC) model.

the helicoidal baskets or Dormia baskets, instruments that are not usually handled by the surgeon (**Figure 3**).

LAPAROSCOPIC CHOLEDOCHOTOMY AND T-TUBE INSERTION

The mastering of this technique is indispensable, because transcystic exploration is not always successful. There are well-defined indications for this approach, which are (1) >10 calculi in the biliary tract, (2) calculi >1cm in size, (3) presence of intrahepatic calculi, and (4) a friable cystic duct.²⁷

In this case, we simulate the biliary tract by using a transparent hose upon which we perform a cut, simulat-

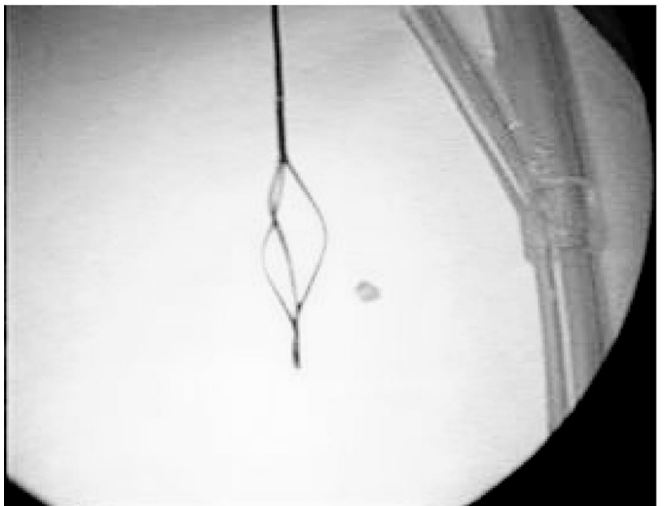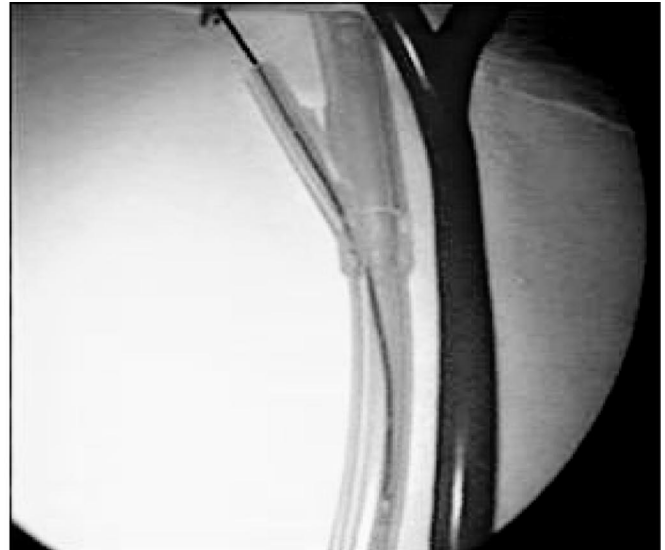


Figure 3. Transcystic duct exploration model.

ing a longitudinal choledochotomy, through which the surgeon proceeds to insert and manipulate the helicoidal basket for practicing capturing and extracting calculi.²⁴

In this model, the surgeon will also have the opportunity to practice 2 of the more difficult steps of laparoscopic common bile duct exploration, that is, placement of the t-tube and handling the suturing and intracorporeal laparoscopic knotting for closure of the choledochotomy (**Figure 4**).

RESULTS

The proposed model allows for the practice of the aforementioned fundamental steps of laparoscopic biliary tract surgery.

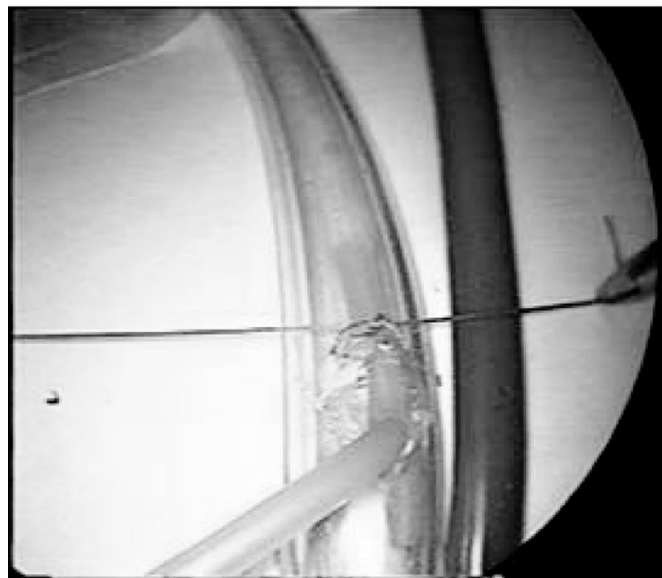
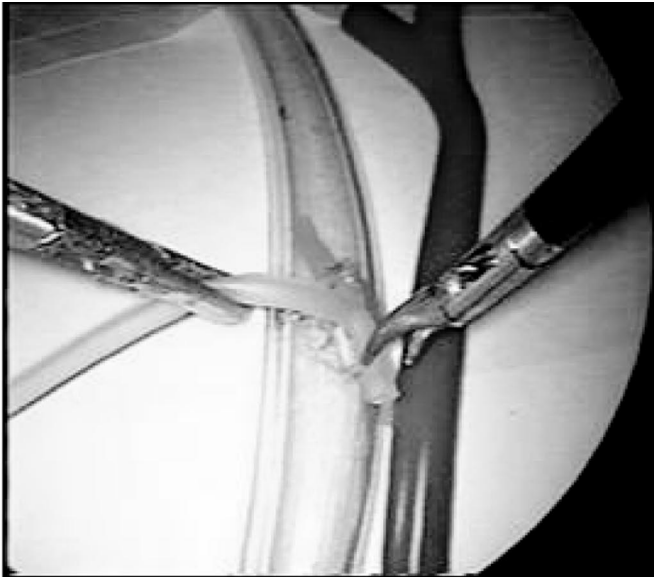


Figure 4. Laparoscopic choledochotomy model.

The likeness of the simulated model technique and the actual live surgery are clearly visible, thus permitting improvement in the surgical team's performance of the steps requiring special skills, which are as follows:

1. Introduction and progression of the cholangiography catheter within the cystic duct (**Figure 5**).
2. Insertion of the Dormia basket through the cystic duct and its progression towards the choledochus, a moment of special concern because inadequate handling could cause lesions of the main biliary tract (**Figure 6**).




Figure 5. Intraoperative cholangiography. In vivo surgery and model view.

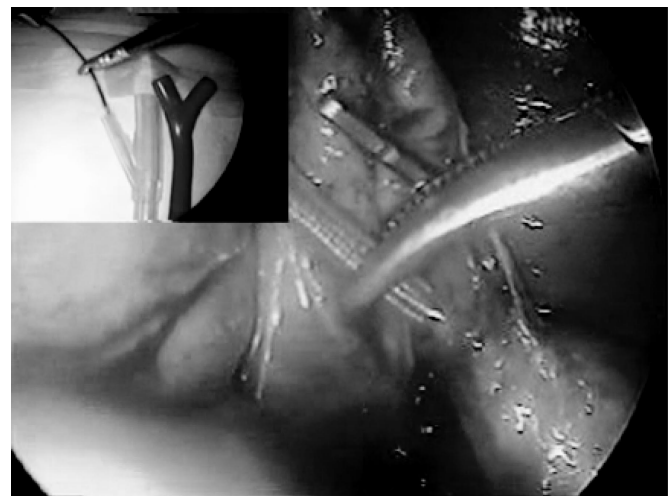

Figure 6. Laparoscopic transcystic duct exploration. In vivo surgery and model view.

3. Handling of helicoidal and Dormia baskets for the capture and extraction of calculi, maneuvers to which the surgeon is not accustomed and are directly related to the success of the procedure and complications, such as trapping of the basket (**Figure 7**).
4. Placement of the t-tube, considered by some to be one of the most grueling steps of the surgery (**Figure 8**).
5. Mastering suturing and intracorporeal knotting is a fundamental factor when advanced laparoscopic surgery is undertaken and is necessary in this particular case for the closure of the choledochotomy over the Kehr tube (**Figure 9**).

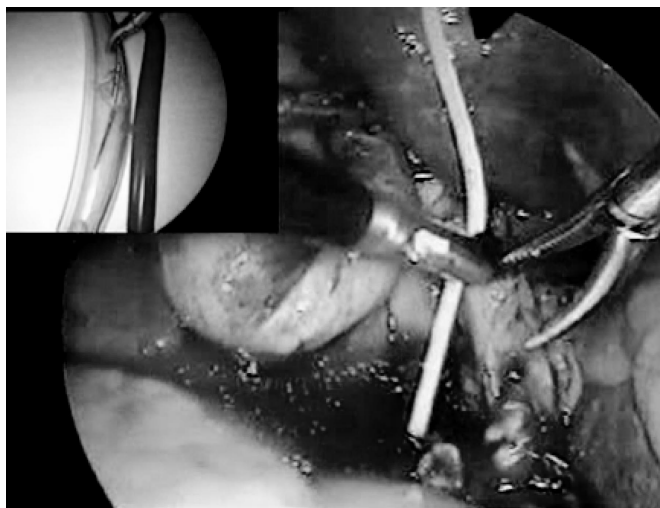


Figure 7. Laparoscopic choledochotomy and common bile duct exploration with basket.

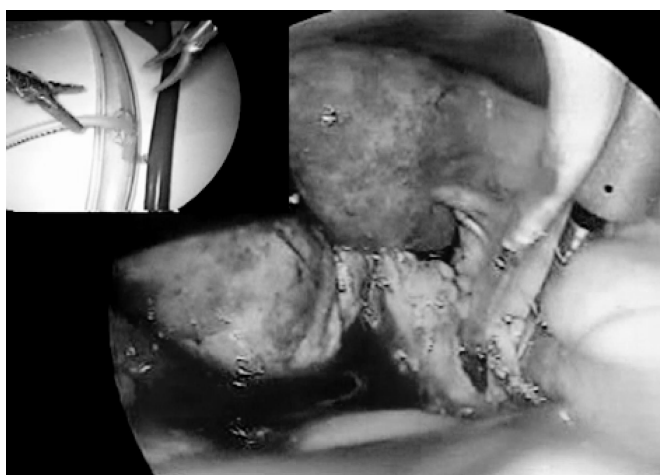

Figure 8. T-tube placement.

6. Handling of 30 degrees by the assistant, taking into account that the adequate exposure and visualization of the surgical field is fundamental for avoiding failure and complications.

Practice using this model has produced better training of the surgical team, which has led to increased effectiveness, diminished surgical time and conversion rate. However, an objective analysis of the impact of this simulator in the learning process is not the purpose of this article. For that end, a prospective controlled study is currently underway.

DISCUSSION

The use of inert training models aimed at lowering the learning curve and even with the purpose of evaluating

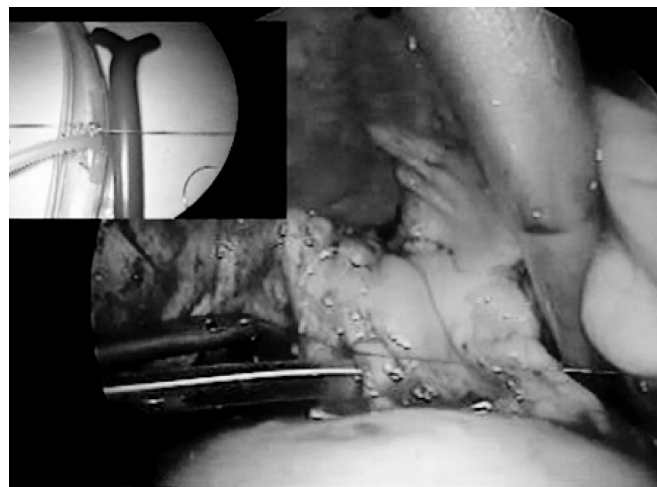

Figure 9. Choledochotomy closure over t-tube.

skills has been described and studied in centers around the globe for many years.²⁸⁻³⁰

Performing advanced laparoscopic surgery requires the acquisition of particular skills within the surgical team, because this kind of approach requires overcoming difficulties that lie with this technique, such as (1) 2-dimensional vision with loss of depth perception, (2) diminished range of movement of instruments compared with those performed freely by the wrists and elbows during open surgery, (3) diminished tactile perception, and (4) the disparity between visual and proprioceptive feedback brought on by hand movements leading to a contrary effect on the opposing end of the instrument, known as the *fulcrum* effect.^{19,31}

Animal models have been traditionally used for practicing this type of surgery²⁴⁻²⁶; however, in the case of the biliary tract, it becomes exceedingly costly because a prior intervention is required and the animal must be kept in captivity for at least a week. The model proposed by Windsor, who used a saphenous magna vein and tributaries to simulate the biliary tract, is hindered by the limited availability of said biological material.³²

The model we propose is simple, low-cost, and readily available, allowing the surgeon to simulate the fundamental steps of surgeries like intraoperative cholangiography, transcystic exploration, and laparoscopic choledochotomy. Performing these steps gives us the chance to practice the necessary skills that will facilitate the adequate accomplishment of this surgery, which is considered very demanding from a technical point of view.²⁷

It is well known that performing simpler surgeries allows for the practice and development of determined skills that help in developing towards more complex procedures. It is a learning process known as transfer of training.³³ Several studies^{33,34} have demonstrated that after practicing on inert models like the one proposed, and mastering certain steps *ex vivo*, adequate training transfer occurs within the operating room, thus reducing failure and complications as well as advancing the learning curve.

Technical advances alongside the development of virtual reality models and specific simulators for high-end procedures^{35,36} could lead to great improvements in laparoscopic surgery training. However, these tend to be of great cost and difficult attainability within our centers.

CONCLUSION

The model proposed is simple, very low-cost, and readily available. It allows for an accurate reproduction of the main steps and maneuvers performed in the laparoscopic common bile duct exploration, aiming at reducing failure and complications. Future studies will be directed towards objectively determining the impact of this model in the development of the learning curve.

References:

- Peters JH, Ellison EC, Innes JT, et al. Safety and efficacy of laparoscopic cholecystectomy. A prospective analysis of 100 initial patient. *Ann Surg.* 1991;213:3–12.
- Perissat J, Collet D, Belliard R, Desplantez J, Magne E. Laparoscopic cholecystectomy. The state of the art. A report on 700 consecutive cases. *World J Surg.* 1992;16:1074–1082.
- Southern Surgeons Club. A prospective analysis of 1518 laparoscopic cholecystectomies. *N Engl J Med.* 1991;324:1073–1078.
- Jacobs M, Verdeja JC, Goldstein HS. Laparoscopic choledocholithotomy. *J Laparoendosc Surg.* 1991;1:79–82.
- DePaula A, Hashiba K, Bafutto M. Laparoscopic management of choledocholithiasis. *Surg Endosc.* 1994;8:1399–1403.
- Berci G, Morgenstern L. Laparoscopic management of common bile duct stones: a multi-institutional SAGES study. *Surg Endosc.* 1994;8:1168–1175.
- Phillips E, Rosenthal R, Carroll B, Fallas M. Laparoscopic trans-cystic common bile duct exploration. *Surg Endosc.* 1994; 8:1389–1393.
- Millat B, Fingerhut A, Deleuze A, et al. Prospective evaluation in 121 unselected patients undergoing laparoscopic treatment of choledocholithiasis. *Br J Surg.* 1995;82:1266–1269.
- Memon MA, Hassaballa H, Memon MI. Laparoscopic common bile duct exploration: The past, the present and the future. *Am J Surg.* 2000;179:309–315.
- Petelin JB. Laparoscopic common bile duct exploration. *Surg Endosc.* 2003;17:1705–1715.
- Ebner S, Rechner J, Beller S, Erhart K, Riegler FM, Szinicz G. Laparoscopic management of common bile duct stones. *Surg Endosc.* 2004;18:762–765.
- Ramirez Lares R. Coledoscopia transcística laparoscópica para la exploración y extracción de cálculos en las vías biliares. *Clin Med HCC.* 1997;2:153–158.
- Mondragón A, Schuleib S. Exploración de vías biliares por laparoscopia *Rev Fac Med UNAM.* 1998;41:187–190.
- Alvarez L, Franco A. Exploración laparoscópica del coledoco. *Rev Colomb Cir.* 1999;14:85–96.
- Sánchez A, Benítez P, Rodríguez O, et al. Exploración laparoscópica de la vía biliar. Primera experiencia en el Hospital Universitario de Caracas. *Rev Venez Cir.* 2004;58:68–77.
- Keeling N, Menzies D, Motson R. Laparoscopic exploration of the common bile duct. Beyond the learning curve. *Surg Endosc.* 1999;13:109–112.
- Bridges M, Diamond D. The financial impact of teaching surgical residents in the operating room. *Am J Surg.* 1999;177: 28–32.
- Reznick R. Teaching and testing technical skills. *Am J Surg.* 1993;165:358–361.
- Scott DJ, Young WN, Tesfay ST, Frawley WH, Rege RV, Jones DB. Laparoscopic skills training. *Am J Surg.* 2001;182:137–142.
- Kirwan W, Kaar T, Waldron R. Starting laparoscopic cholecystectomy. The pig as a training model. *Ir J Med Sci.* 1991;160: 243–246.
- Wu J, Strasberg S, Luttmann D, Meininger T, Talcott M, Soper N. Laparoscopic hepatic lobectomy in the porcine model. *Surg Endosc.* 1998;12:232–235.
- Tsimoviannis E, Siakas P, Tassis A, Glantzounis G, Gogos, Mousafiri U. Laparoscopic modified Sugiura procedure: experimental study on the pig. *Int Surg.* 1997;82:312–315.
- Jensen AR, Milner R, Gaughan J, Grewal H. An inexpensive *ex-vivo* porcine laparoscopic Nissen fundoplication training model. *JLS.* 2005;9:322–327.
- Cameron B, O'Regan P, Anderson D. A pig model for advanced laparoscopic biliary procedures. *Surg Endosc.* 1994;8: 1423–1424.
- Watson D, Treacy P, Williams A. Developing a training model for laparoscopic common bile duct surgery. *Surg Endosc.* 1995; 9:1116–1118.

26. Pekolj J, Mazza O, Beskow A, et al. Modelo experimental de exploración laparoscópica de la vía biliar en credos. *Rev Argent Cir.* 1999;76:147-154.
27. Lyass S, Phillips E. Laparoscopic transcystic duct common bile duct exploration. *Surg Endosc.* 2006;20(suppl 2):S441-S445.
28. Derossis A, Fried G, Abrahamowicz M, Sigman H, Barkun J, Meakins J. Development of a model for training and evaluation of laparoscopic skills. *Am J Surg.* 1998;175:482-487.
29. Keyser E, Derossis M, Antoniuk M, Sigman H, Fried M. Simplified simulator for the training and evaluation of laparoscopic skills. *Surg Endosc.* 2000;14:149-153.
30. Fraser S, Klassen R, Feldman D, Ghitulescu D, Stanbridge D, Fried G. Evaluating laparoscopic skills. *Surg Endosc.* 2003;17:964-967.
31. Smith D, Farrell T, McNatt S, Metreveli R. Assessing laparoscopic manipulative skills. *Am J Surg.* 2001;181:547-550.
32. Windsor JA. Laparoscopic exploration of the common bile duct: a training model. *J R Coll Surg Edin.* 1993;38:48-49.
33. Figert P, Park A, Witzke D, Schwartz R. Transfer of training in acquiring laparoscopic skills. *J Am Coll Surg.* 2001;193:533-537.
34. Hyltander A, Liljegren E, Rhodin O, Lonroth H. The transfer of basic skills learned in a laparoscopic simulator to the operating room. *Surg Endosc.* 2002;16:1324-1328.
35. Tendick F, Downes M, Cavusoglu C, Gantert W, Way L. Development of virtual environments for training skills and reducing errors in laparoscopic surgery. *Proceedings of the SPIE International Symposium on Biological Optics.* San Jose CA: 1998;36-44.
36. Basdogan C, Ho C, Srinivasan A. Virtual environments for medical training: graphical and haptic simulation of laparoscopic common bile Dutch exploration. *Transactions on Mechatronics.* 2001;6:269-285.
37. Maithel S, Sierra R, Korndorffer J, et al. Construct and face validity of MIST-Vr, Endotower and CELTS. *Surg Endosc.* 2006; 20:104-112.